PULP FICTION

A Quarterly Newletter

By Westside Endodonics

FALL 2013

Steven Singh DDS

## Greetings!

Well, I am going to say it…summer is officially over and I hope everyone had a safe season. I hope you enjoy fall as much as I do. I think growing up in the Northwest you get a sense of appreciation for the return of the cooler temperatures and everything else that comes with this season. It is so hard to believe that we are into our four quarter already! Where has this year gone? It seems not so long ago that we had celebrated our annual Holiday Party! As we try to finish out the year, I have been on a mission to reach out to as many of you as possible. My staff is attempting to set up lunches or dinners so I can have the pleasure of getting to know you better. I thank all of you that entrust your patients in the care we provide…especially when that patient is you! And once again…I am in that winemaker's mode. Crush is here! That means grape harvesting and squeezing! Enjoy the Fall 2012 edition of Pulp Fiction!!!

## Diabetes Mellitus and Inflammatory Periapical Lesions

Diabetes mellitus (DM) is a complex, progressive and debilitating disease that promotes wound healing difficulties, as well as systemic and oral manifestations that have a direct effect on pulp and periapical tissue. Patients with uncontrolled DM are susceptible to bone metabolism alterations, peripheral neuropathy, vascular insufficiency, autonomic dysfunction and anaerobic infection caused by reduced oxygen diffusion through the capillary wall. Lima et al from the Catholic University of Brasília, Brazil, evaluated the influence of DM on periapical bone resorption, providing clinical and laboratory data from research involving periapical pathosis in patients with DM and the glucose effect in distinct cells.

Hyperglycemia can alter pulp structures because of impaired collateral circulation, which leads to an increased risk of necrosis, along with toothache and an occasional tendency toward pulp necrosis caused by ischemia. The disease may also cause structural modifications in pulp tissue, such as reducing the concentration of collagen, increasing the thickness of the basement membrane of blood vessels, angiopathy, higher frequency of calcifications, and obliterative endarteritis.

DM patients exhibited an increased risk of a reduced defense response to pathogens in periapical tissue, along with an increased susceptibility to residual lesions after root canal treatment and a higher prevalence of periapical lesions than in nondiabetic patients. Other clinical and radiographic studies reported a higher prevalence of periapical lesions in patients with DM. Uncontrolled DM implies an absence of the healing process and a progression of posttreatment endodontic lesions. An epidemiological study of approximately 4500 Native American patients with DM revealed a decrease in tooth retention associated with root canal treatment and an increase in retreatment associated with the presence of disease. A cross-sectional study using radiographic analysis of Brazilian adults with and without type 2 DM demonstrated that the former had an enhanced incidence of apical periodontitis in non-endodontically treated teeth. Diabetic patients treated for root canal infections showed decreased success and increased flare-ups. However, the relationship between poorly controlled diabe tes and periapical lesions remains unclear.

**Conclusion**

Inadequate DM control may predispose affected patients to dental pulp infections. This relationship demonstrates a cross-susceptibility between DM and apical periodontitis, which increases the clinical rate of endodontic treatment failure. The characteristics of periapical lesions of DM patients show that the targets of success in these patients should be based on careful assessments and effective antimicrobial regimens of the root canal. Clinical and basic studies could help raise endodontic success rates for these patients.

*Lima SMF, Grisi DC, Kogawa EM, et al. Diabetes mellitus and inflammatory pulpal and periapical disease: a review. Int Endod J 2013;doi:10.1111/iej.12072.*

## Revascularization of Immature Teeth with Necrotic Pulps

Immature teeth with necrotic pulps are challenging to treat, because with root canal debridement and filling, the remaining thin dentinal wall increases the risk of subsequent tooth fracture. Management has typically involved apexification with calcium hydroxide treatment or the placement of mineral trioxide aggregate (MTA) apical plugs, but neither solves the problem of the thin and weak dentinal root canal walls. Regeneration of pulpal tissues that could produce continued root development would be the ideal treatment for such immature teeth.

The periapical tissues around the apices of immature teeth have a rich blood supply and contain stem cells that have the potential to regenerate pulp tissue in response to tissue injury. However, microbial eradication of the infected canal space is essential for successful revascularization procedures.

**FALL 2013**

**Inside this issue:**

- Message from Dr Singh
- Diabetes Mellitus and Inflammatory Periapical Lesions
- Revascularization of Immature Teeth with Necrotic Pulps
- Bisphosphonates and Endodontic Therapy
- Morphology of Mesiobuccal Root Canal Systems

**(continued from front)**
To assess the regenerative potential of permanent immature teeth with necrotic pulps, Tawfik et al from Ain Shams University, Egypt, applied several treatment protocols to 9 mongrel dogs. Necrotic pulps and periapical pathosis were created by infecting 108 immature teeth with 216 root canals. The teeth were divided into equal groups according to the evaluation period length (1 week, 3 weeks, 3 months) and each was further subdivided by different treatment protocols:

- **Subgroup 1:** MTA apical plug, glass ionomer (GI) coronal seal
- **Subgroup 2:** revascularization by blood clot, MTA, GI coronal seal
- **Subgroup 3:** revascularization by blood clot enhanced with injectable scaffold coated with basic fibroblast growth factor (bFGF), MTA, GI coronal seal
- **Subgroup 4:** MTA over empty canal (no blood clot), GI coronal seal
- **Subgroup 5:** positive control (canals left open to oral cavity)
- **Subgroup 6:** negative control (untreated vital teeth)

All root canals were disinfected with a triple antibiotic paste prior to treatment, with the exception of the 2 control subgroups.

The root length, thickness and apical diameter were measured from radiographs after the dogs were euthanized. Histological evaluation assessed the inflammatory reaction, soft and hard tissue formation.

After 3 months, 67% of subgroup 2 samples and 75% of subgroup 3 samples had increased in length and thickness. The difference in length observed between subgroup 2 and subgroup 3 and the other treated groups can be attributed to hard tissue deposition and consequent apical closure.

At 3 months, no significant difference in thickness of the root was found between subgroups 2 and 3. The untreated group was significantly different from the other groups and displayed normal tooth development.

**Conclusion**
The hard tissue deposited in the root canals was characterized by inclusion of cementum-like cells, direct attachment to dentine and fibrous attachment to neighboring connective tissue. A blood clot was beneficial for revascularization because it supplied the new tissue with growth factors. The hydrogel scaffold incorporating bFGF did not appear to play a significant role in the regeneration process.

*Tawfik H, Abu-Seida AM, Hashem AA, Nagy MM. Regenerative potential following revascularization of immature permanent teeth with necrotic pulps. Int Endod J 2013;doi:10.1111/iej.12079.*

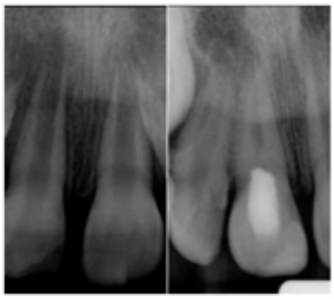

**Figure 1.** Image of tooth with necrotic pulp before revascularization (left) and after postoperative follow-up (right). (*Images courtesy of Drs. David Prusakowski and Frederic Barnett.*)

## Bisphosphonates and Endodontic Therapy

Bisphosphonates (BPs) are nonmetabolized analogues of pyrophosphates that are often prescribed to treat patients with bone disorders, such as osteoporosis and Paget's disease. BPs are also prescribed to control pain, fractures and hypercalcemia from bone invasion in multiple myeloma or bone metastasis in other malignancies.

BP-related osteonecrosis of the jaw (BRONJ) is associated with the administration of these drugs. Dental procedures (e.g., dental extraction or invasive surgical procedures) are risk factors for the development of BRONJ. Moinzadeh from the University of Amsterdam, the Netherlands, et al reviewed the factors that may play a role in the development of osteonecrosis of the jaw in patients treated with BPs and undergoing nonsurgical endodontic treatment, as well as some recommendations for its prevention.

Even though the occurrence of BRONJ is considered to be rare, its consequences for the patient can be catastrophic. Therefore, while performing nonsurgical endodontic treatment on patients medicated with BPs and at risk of developing BRONJ (as classified in 2009 by the American Association of Maxillofacial Surgeons [AAOMS]; Table 1), the following recommendations are suggested:

Even though the occurrence of BRONJ is considered to be rare, its consequences for the patient can be catastrophic. Therefore, while performing nonsurgical endodontic treatment on patients medicated with BPs and at risk of developing BRONJ (as classified in 2009 by the American Association of Maxillofacial Surgeons [AAOMS]; Table 1), the following recommendations are suggested:

- A 1-minute mouth rinse with chlorhexidine prior to treatment would lower the bacterial load of the oral cavity and decrease the chance of bacteremia caused by any soft tissue trauma.
- The use of anesthetic agents with vasoconstrictors should be avoided because BPs already exert an antiangiogenic action.
- Working under aseptic conditions is mandatory.
- Particular care should be taken to avoid damage to the gingival tissues during rubber dam clamp placement.
- Patency of the apical foramen should be avoided because it could elevate the risk of bacteremia.
- Techniques that lower the risk of overfilling and overextension of the filling material are recommended.
- Balance the risk of developing BRONJ against the risk of adverse events from antibiotic prophylaxis. In cases of necrotic pulps in patients treated with IV BPs or medicated with oral BPs, for more than 3 years with concomitant risk factors, single-dose antibiotic prophylaxis may be advocated, because the adverse effects of recommended antibiotics, once allergies have been ruled out, are minimal.

Osteonecrosis of the jaw has also been observed in patients medicated with denosumab, a monoclonal antibody used against RANKL (receptor activator of nuclear factor-kappaB ligand).

**Conclusion**
BPs are commonly and widely prescribed to treat various bone pathologies. Because endodontic therapy has not been identified as a significant risk factor for promoting BRONJ, it is considered to be the favored alternative to extraction when possible. However, more studies are needed to ascertain the safety of nonsurgical endodontic treatment in patients at risk of BRONJ.

*Moinzadeh A-T, Shemesh H, Neirynck NAM, et al. Bisphosphonates and their clinical implications in endodontic therapy. Int Endod J 2013;46:391-398.*

## Morphology of Mesiobuccal Root Canal Systems

Often, the mesiobuccal (MB) root of an endodontically treated maxillary first molar is associated with posttreatment periapical radiolucency and requires retreatment. The causes of root canal failure vary, but a missed root canal may play a significant role. The MB root canal system is complex and may include accessory canals, intercanal

communications, apical fins, deltas and ramifications. To suggest a "gold standard" method for in-depth study of root canal morphology, Chang et al from Kyung Hee University, South Korea, investigated the following methodologies used for root canal morphology study:

- **Clearing technique:** Teeth were decalcified in acid, dehydrated in alcohol and placed in methyl salicylate to render them transparent. Dye was then used to illustrate the root canal anatomy. Because some root canal anatomy may be too narrow to allow the dye solution to penetrate, this method would fail to demonstrate all the canal anatomy.

- **Endodontic cube technique:** The tooth is embedded in clear acrylic resin, which is then sectioned into 1-mm-thick slices that are individually examined with a stereomicroscope. The technique's main disadvantages are that tooth structure loss is inevitable and some small accessory canals could be removed or blocked in the tooth-slicing process.

**Table 1.** *Classification for the diagnosis of BRONJ as proposed by the AAOMS*

| Stages | Description |
|---|---|
| At-risk category | The patient has been treated with BPs (either oral or IV), and there is no apparent necrotic bone. |
| Stage 0 | Presence of nonspecific clinical findings and symptoms, and no clinical evidence of bone necrosis. |
| Stage 1 | Presence of exposed and necrotic bone in asymptomatic patients and no evidence of infection. |
| Stage 2 | Presence of exposed necrotic bone associated with infection (pain and erythema, with or without purulent drainage). |
| Stage 3 | Presence of exposed necrotic bone, pain, infection and 1 of the following clinical manifestations: exposed and necrotic bone extending beyond the region of alveolar bone, resulting in pathologic fracture, extraoral fistula, oral antra/oral nasal communication or osteolysis extending to the inferior border of the mandible or the sinus floor. |

- **Cone-beam computed tomography (CBCT):** Limited-volume CBCT can provide noninvasive 3-dimensional (3D) images, but because of its relatively low resolution, detailed reproduction of fine root canal morphology images may be limited.

- **Micro-computed tomography (MCT)** with thin-slab minimum-intensity projection (TS-MinIP): With a voxel resolution of 50 to 1 µm, MCT is an effective tool to study complex root canal morphologies. The greatest advantage of this technique is that air or low-attenuation structure is emphasized in contrast to surrounding high-attenuation structure. Even when anatomic structures are tortuous or twisted, the lumen is seen as patent and continuous in the TS-MinIP images.

- **MCT with 3D volume rendering:** The advantage of this technique is that it can visualize small accessory canals and minute root canal structures.

The research also shows that differences in the morphology of MB root canals in maxillary first molars exist among various ethnicities. Age also affects MB root canal morphology. The existence of a second MB canal in a Korean population in their 20s can be as high as 80%, whereas for people in their 60s, it can be as low as 50%-most likely from calcification and dentin deposition.

**Conclusion**

Because MCT study clearly shows the fine anatomical structures in the MB root, TS-MinIP combined with 3D volume rendering analysis can be considered the "gold standard" for in-depth morphologic study of complex root canal system in endodontology.

*Chang S-W, Lee J-K, Lee Y, Kum K-Y. In-depth morphological study of mesiobuccal root canal systems in maxillary first molars: review. Restor Dent Endod 2013;38:2-10.*